

Peritoneal Tuberculosis Mimicking Ovarian Cancer: A Report of Two Cases

Zohreh Yousefi,^{1*} Shohreh Saied,² Amir Hosein Jafarian,³ and Jelveh Jalili⁴

¹Professor of Obstetrics and Gynecology, Fellowship of Gynecologist Oncologist, Ghaem Hospital, Mashhad University of Medical Sciences, Mashhad, Iran

²Fellowship of Gynecologist Oncologist, Department of Obstetrics and Gynecology, Ghaem Hospital, Mashhad University of Medical Sciences, Mashhad, Iran

³Anatomo-clinical Pathologist, Associated Professor of Pathology, Ghaem Hospital, Mashhad University of Medical Sciences, Mashhad, Iran

⁴Resident of Obstetrics and Gynecology, Ghaem Hospital, Mashhad University of Medical Sciences, Mashhad, Iran

*Corresponding author: Zohreh Yousefi, Department of Obstetrics and Gynecology, Ghaem Hospital, Mashhad University of Medical Sciences, Mashhad, IR Iran. Tel: +98-5118012477, Fax: +98-5118430569, E-mail: yousefiz@mums.ac.ir

Received 2016 August 03; Accepted 2016 August 20.

Abstract

Introduction: Peritoneal tuberculosis (PTB) and ovarian cancer have overlapping nonspecific symptoms and signs. No pathognomonic clinical features or imaging findings can help to distinguish definite diagnosis of extra pulmonary TB. Peritoneal TB can be easily confused with peritoneal carcinomatosis or advanced ovarian carcinoma; therefore, it is difficult to distinguish these two entities. The current study described two cases of peritoneal tuberculosis mimicking advanced ovarian cancer.

Case Presentation: In the first case, the initial manifestation was lower abdominal pain. The imaging indicated ovarian mass, ascites and hepatic surface nodularity, omental and peritoneal thickening. Also, titer of tumor marker CA-125 was more than 600 units. In laparoscopy, disseminated peritoneal seeding was observed. Frozen section of sampling these lesions reported tuberculosis. Biopsy of ovarian mass reported fibrothecoma. Concurrent with this patient, the second case referred to the same center, Department of Gynecology Oncology at Ghaem Hospital, Mashhad University, Iran, in 2015. Her presentation was fever and remarkable weight loss during the last three months. She had a multiloculated pelvic mass with septation in sonography and peritoneal seeding with pleural effusion in computed tomography (CT) scan. Peritoneal tuberculosis was recognized through laparotomy and both patients received anti-TB treatment and now they are in good health status.

Conclusions: Peritoneal tuberculosis should always be considered in differential diagnosis of patients with evidences suggesting advanced ovarian cancer.

Keywords: Ovarian Cancer, Peritoneal Tuberculosis, Tuberculosis

1. Introduction

Tuberculosis (TB) is one of the major global public health problems. It is estimated that about one-third of the world population are infected by latent TB (1). Approximately, 95% of TB cases occur in the developing countries in Africa and Asia. According to the world health organization (WHO) in 2013, nine million individuals were infected with TB and 1.5 million died; 20% of all dead cases were extra-pulmonary TB (2). A retrospective study in a period of 20 years reviewed the pathologic report of genital tract tuberculosis. They found that the frequency of peritoneal tuberculosis (PTB) was 13% (3). Oge et al. reported that 20 patients were preoperatively suspected of having ovarian malignancy but their pathological results revealed PTB (4). However, Chen-Hsuan et al. (cited in Onofriescu et al.) reported 17 patients with peritoneal TB that their initial presentation was a mimic of advanced ovarian cancer (5, 6). Therefore, it is needed to be aware of peritoneal TB as a

differential diagnosis of pelvic masses along with ascites or peritoneal seeding especially in the Middle East where increased rate of tuberculosis exists. Peritoneal TB may be mistaken easily with peritoneal carcinomatosis or advanced ovarian carcinoma; however, laparotomy is usually mandatory to diagnose these diseases. This report introduces two cases of PTB mimicking advanced ovarian cancer.

2. Case Presentation

2.1. Case 1

A 55-year-old multiparous female with lower abdominal pain from two months before the study, and a sonography report of an ovarian mass, small amount of ascites and hepatic surface nodularity was referred to the Department of Gynecology Oncology at Ghaem Hospital, Mashhad University of Medical Sciences, Mashhad, Iran, in Feb 2015. She

had no complaint of anorexia, nausea, vomiting and urinary disorder, no history of low grade fever and weight loss. In bimanual physical examination, a firm large mass was palpated in right side of pelvis. Tumor marker CA-125 was reported more than 600 units; other tumor markers such as CEA and Inhibin were in normal range. Computed tomography (CT) scan revealed small size of ascites and a homogenous hypodense mass in right adnexa with fat stranding in omentum along with peritoneal thickening in the left paracolic gutter. Her chest X-ray was normal. Tuberculin skin test (TST) was negative. Due to clinical and imaging findings, suggestive of an inoperable ovarian cancer, percutaneous ultrasound -guided biopsy from omentum revealed chronic granulomatous inflammation. After the initial evaluation, the patient underwent laparoscopy. Very small amount of ascites, diffuse peritoneal seeding involving liver and sub diaphragmatic surface and a solid ovarian mass were observed in the left ovary. Frozen section revealed ovarian fibrothecoma and TB in biopsy from peritoneal seeding (Figure 1). The permanent pathology report confirmed the primary pathology; therefore, anti-tuberculosis treatment was applied. Initial therapy was recommended with regimen of isoniazid (INH), rifampin (RIF) and pyrazinamide (PZA) for two months followed by INH and RIF for four months and continued with INH + RIF daily for nine months.

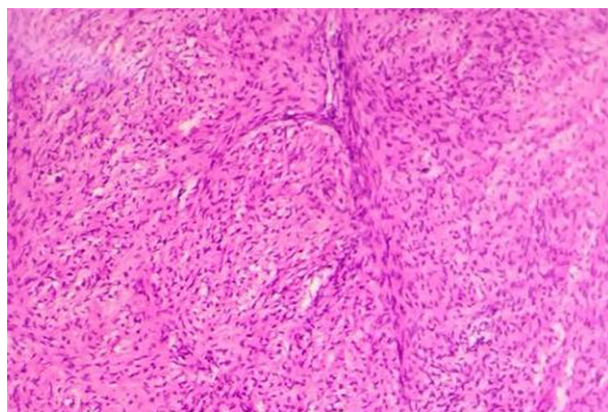


Figure 1. Histologic Review of fibrothecoma for the First Patient Shows Theca Cells Merge With Spindle Cell Area Characteristic of Fibroma; H & E Staining $\times 100$

2.2. Case 2

A 24-year-old virgin from North-East of Khorasan province, Iran, with an about 20 cm multiloculated and septated pelvic mass; peritoneal seeding and pleural effusion in CT scan was referred to the department simultaneously with the first case. She had low fever and remarkable weight loss during the last six months; in addition

to increased abdominal girdle and three months of amenorrhea. In physical examination, she was a cachectic female with no discrete palpated mass in abdominal examination and no lymphadenopathy, but in rectal exam there was a suspicious mass in the left pelvic area non adhesion to rectum. Tumor marker CA-125 was more than 1000 units and other markers were at normal level. She had different white blood cell (WBC) counts most of which was about 15,000 with 85% neutrophil. In the CT scan, the fat plan between the mass and bowel loops was lost and very small gas bubbles were reported in pelvic mass suggesting perforation of the bowel (Figures 2 and 3). Pleural effusion was negative for malignancy and also BK bacilli. Blood and purified protein derivative (PPD) skin tests were negative. With anticipation of an advanced ovarian cancer, she underwent laparotomy. All surfaces of peritoneum were filled with caseous necrotic substance. Frozen section and final pathology report was peritoneal TB (Figure 4). After a few weeks of anti-tuberculosis treatment, good clinical response was observed. Now, both of them are in good health status. These cases were reported after obtaining informed consent from both patients.

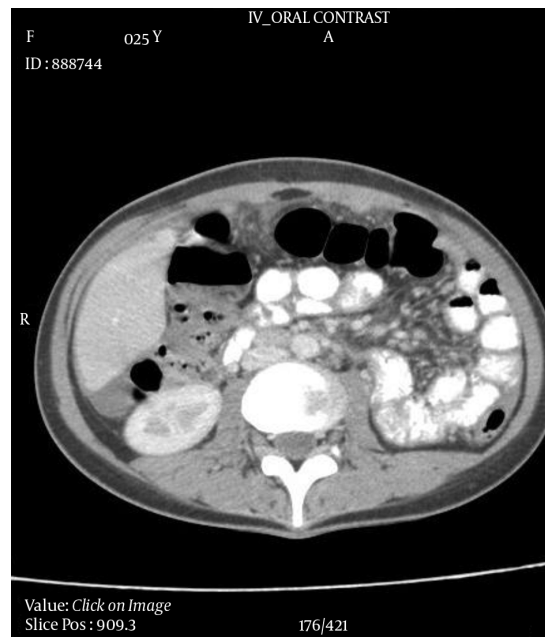

Figure 2. CT Scan of the Second Patient Shows Multiple Lymphadenopathies in Meso-Epithelial of the Small Bowel

3. Discussion

Identification of pelvic mass associated with ascites, high CA-125 levels and peritoneal seeding strongly suggest

pelvic malignancies. Due to various clinical presentations of TB and being a relatively uncommon event, it is generally difficult to diagnose peritoneal TB. But, it is reasonable to consider the possibility of this disease and accordingly prevent unnecessary surgery. The peritoneum is one of the most common extra pulmonary sites of tuberculosis infections. Risk factors for extra pulmonary TB is not clear; about 12% of patients with peritoneal TB have no risk factors (7). The study of Sanches et al. revealed that age

> 40 years old, female gender, HIV infection and previous liver disease were the independent risk factors for extra pulmonary TB (7). The current study did not find any risk factors for the patients except endemic area. The postulated mechanisms by which the tubercular bacilli reach the peritoneal cavity are hematogenous spread or direct spread from the contiguous infected sites such as small intestine, lymph nodes, and fallopian tubes or rarely by venereal transmission (8). In 2009, medical records of 55 patients suspected with ovarian malignancies unsuitable for optimal debulking were selected and report of ultrasound guided core biopsies were reviewed. The results showed that tuberculosis was the second most common disease (14.5%) after primary ovarian tumors (65.5%) (9). Ovarian cancer is a serious condition and preoperative diagnosis is difficult. Non-invasive methods, such as tuberculin skin test, chest radiographs or acid-fast staining and culturing or Ziehl-Neelsen staining of the ascites fluid are usually insufficient to provide the diagnosis of peritoneal or pelvic TB. Although nonspecific and overlap symptoms of peritoneal TB with advanced ovarian carcinoma are confusing, it seems that the best approach to obtain tissue sampling are ultrasound or CT-guided peritoneal biopsy, laparoscopy or laparotomy (10). It seems that these methods are the least-invasive approaches to avoid unnecessary extended surgery in such patients. It was noted that patient's age may be helpful to diagnose TB from ovarian cancer. TB mostly occurs at reproductive ages (20 - 40 years), while ovarian cancer happens at older ages. In addition, weight loss which is uncommon in advanced ovarian cancer is impressive in TB. Also, history of pregnancy is an important factor because unlike peritoneal TB, history of primary infertility is seldom encountered in patients with ovarian cancer. It is important that after confirming the diagnosis of peritoneal TB and rule out the involvement of other sites; effective treatment should be planned for anti-tuberculosis medication. The treatment of peritoneal TB is the same as that of pulmonary TB (11). A good prognosis is expected with an early diagnosis, except for patients at an advanced age or with a poor medical condition. Good outcomes in both patients of the current study were achieved by this treatment.

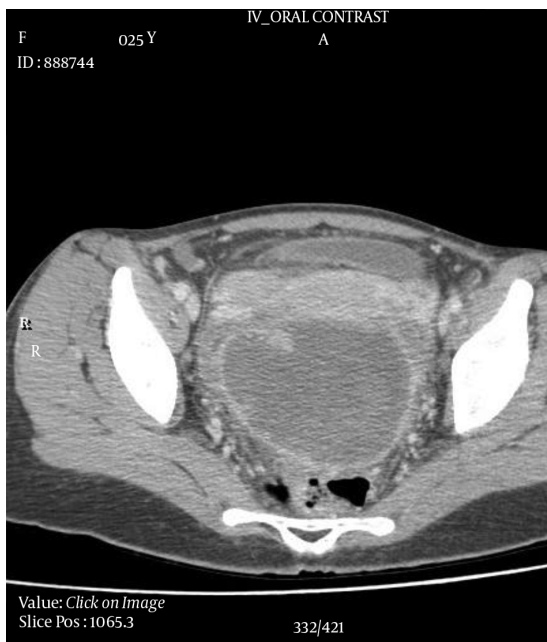

Figure 3. Pelvic Mass of the Second Patient; a Cystic Mass With Thick Wall and Mural Nodule Between Uterus and Rectum

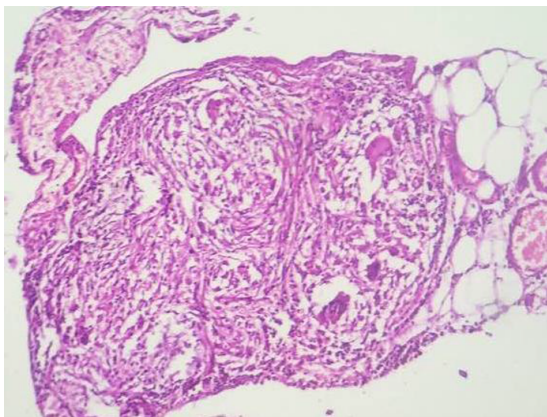


Figure 4. Histologic Review of Abdominal Mass of the Second Patient Shows Peritoneal Tissue With Granulomatous Inflammation; H & E staining $\times 100$

3.1. Conclusions

It seems that a high index of suspicion of extra pulmonary tuberculosis due to its high incidence in the under developing countries, unusual manifestations of peritoneal TB, and symptoms similar to that of ovarian carcinoma should be considered.

References

- Gupta AN, Shivashankara KN. Pelvic-peritoneal tuberculosis presenting as an adnexal mass and mimicking ovarian cancer. *ATMPH*. 2013;**6**(1):117.
- Hasanzadeh M, Naderi HR, Hoshyar AH, Shabane S, Shahidsales S. Female genital tract tuberculosis presenting as ovarian cancer. *J Res Med Sci*. 2014;**19**(2):184–9. [PubMed: 24778675].
- Wu CH, Changchien CC, Tseng CW, Chang HY, Ou YC, Lin H. Disseminated peritoneal tuberculosis simulating advanced ovarian cancer: a retrospective study of 17 cases. *Taiwan J Obstet Gynecol*. 2011;**50**(3):292–6. doi: 10.1016/j.tjog.2011.07.006. [PubMed: 22030041].
- Oge T, Yalcin OT, Ozalp SS, Kebapci M, Aydin Y, Telli E. Sonographically guided core biopsy: a minimally invasive procedure for managing adnexal masses. *J Ultrasound Med*. 2013;**32**(11):2023–7. doi: 10.7863/ultra.32.11.2023. [PubMed: 24154907].
- Onofriescu M, Luca A, Berescu A, Carp A, Dumitrescu A. Peritoneal tuberculosis difficulties of the differential diagnosis case report. *Euro Sci J*. 2014;**10**(9).
- Tipirneni N, Siegel MO. Pulmonary and peritoneal tuberculosis associated with tumor necrosis factor-alpha inhibitor use: a case report and review of the literature. *Case Rep Pulmonol*. 2012;**2012**:598634. doi: 10.1155/2012/598634. [PubMed: 23304607].
- Sanchez I, Carvalho A, Duarte R. Who are the patients with extrapulmonary tuberculosis?. *Rev Port Pneumol (2006)*. 2015;**21**(2):90–3. doi: 10.1016/j.rppnen.2014.06.010. [PubMed: 25926372].
- Oge T, Ozalp SS, Yalcin OT, Kabukcuoglu S, Kebapci M, Arik D, et al. Peritoneal tuberculosis mimicking ovarian cancer. *Eur J Obstet Gynecol Reprod Biol*. 2012;**162**(1):105–8. doi: 10.1016/j.ejogrb.2012.02.010. [PubMed: 22397744].
- Yassae F, Farzaneh F. Familial tuberculosis mimicking advanced ovarian cancer. *Infect Dis Obstet Gynecol*. 2009;**2009**:736018. doi: 10.1155/2009/736018. [PubMed: 20052396].
- Ilhan AH, Durmusoglu F. Case report of a pelvic-peritoneal tuberculosis presenting as an adnexal mass and mimicking ovarian cancer, and a review of the literature. *Infect Dis Obstet Gynecol*. 2004;**12**(2):87–9. doi: 10.1080/10647440400003568. [PubMed: 15739822].
- Gupta T, Gupta S, Bhatia P, Gupta N. Pelvic Tuberculosis Mimicking Ovarian Malignancy: A Case Report. *India J Clin Prac*. 2013;**24**(5):456–8.