



# Heterotopic Pregnancy: A Case Report

## ARTICLE INFO

**Article Type**  
Case Report

### Authors

Forough Javanmanesh\*<sup>1</sup> MD,  
Mina Moeini<sup>1</sup> MD

### How to cite this article

Forough Javanmanesh, Mina Moeini. Heterotopic Pregnancy: A Case Report. Journal of Obstetrics, Gynecology and Cancer Research. 2018;3(3):133-135.

## ABSTRACT

**Introduction** Heterotopic pregnancy or combination of intra and extra- uterine pregnancy is very rare, but its incidence increased sharply in recent years due to the development of medically assisted reproductive technology. This condition carries a significant maternal morbidity and mortality due to the risk of rupture of ectopic pregnancy. This study was a case report of heterotopic pregnancy.

**Patient Information** A 25 year old pregnant woman with abdominal pain and nausea and vomiting was admitted in 12 March 2018 in Firoozgar hospital that ultrasound examination suggested heterotopic pregnancy and laparotomy and left salpingectomy was performed, and intrauterine pregnancy continued.

**Conclusion** A high index of suspicion can help in timely diagnosis and appropriate intervention and decrease the risk of complications and maternal mortality.

**Keywords** Heterotopic Pregnancy; Acute Abdomen; Pelvic Mass

<sup>1</sup>Obstetrics & Gynecology Department, Medicine Faculty, Iran University of medical science, Tehran, Iran

### \*Correspondence

Address: Obstetrics & Gynecology Department, Medicine Faculty, Iran University of medical science, Tehran, Iran. Postal Code: 1593748711  
Phone: +98 (21) 82141301  
Fax: +98 (21) 88942622  
dr.fjavanmanesh@yahoo.com

### Article History

Received: January 30, 2018  
Accepted: March 11, 2018  
ePublished: September 22, 2018

## CITATION LINKS

[1] Cornual heterotopic pregnancy: A case report [2] Incidence and risk factors for ectopic pregnancy [3] Heterotopic pregnancy after ovulation induction and assisted reproductive technologies: A literature review from 1971 to 1993 [4] Heterotopic interstitial pregnancy: A case report [5] Management and obstetric outcomes of 17 heterotopic interstitial pregnancies [6] Delayed detection of spontaneous bilateral tubal ectopic pregnancies after methotrexate treatment [7] Unforeseen consequences of the increasing rate of cesarean deliveries: Early placenta accreta and cesarean scar pregnancy, a review [8] Obstetric and neonatal outcome of multifetal pregnancy reduction [9] Obstetric outcomes in reduced and non-reduced twin pregnancies, a single hospital experience [10] Normal vaginal delivery at term after expectant management of heterotopic caesarean scar pregnancy: A case report [11] Naturally occurring heterotopic pregnancy in a multiparous patient: A case report

## Heterotopic Pregnancy: A Case Report

### Introduction

Heterotopic pregnancy is the existence of two simultaneous pregnancies with separate implantation site, one of which is a viable intrauterine pregnancy and the other of which is non-viable ectopic pregnancy.

Heterotopic pregnancy is very rare in natural conception (1/10000-1/30000 pregnancies) [1, 4], but it is most common in couples who conceive with assisted reproductive procedures like IVF as many as 1/3900 pregnancies [2], and there are cases of heterotopic interstitial pregnancy [3, 5], a high index of suspicion can help in timely diagnosis and appropriate intervention.

A woman experiencing a heterotopic pregnancy may or may not have symptoms. This is especially concerning since half of these pregnancies only diagnosed when the fallopian tube ruptures. If symptoms are present, they may include: abnormal vaginal bleeding, mild to severe abdominal pain or cramping, dizziness, fainting, nausea and vomiting and bloating.

Diagnosis of heterotopic pregnancy is very difficult in its early stages, women may have vaginal bleeding and cramping, but these are symptoms that occur in a normal pregnancy, at the same time it is easy to miss a heterotopic pregnancy during a routine ultrasound since the technician may only check the developing fetus intrauterine.

If there is a suspicion of a heterotopic pregnancy, it usually is only by week four or five that it can be confirmed or to ruled out by ultrasound. This study was a case report of a 25-year-old woman with a heterotopic pregnancy.

### Patient Information

A 25-year-old pregnant woman (G1 P0) with abdominal pain and nausea and vomiting was admitted on 12 March 2018 in Firoozgar hospital. Based on the last menstrual period (LMP) of 12 January, gestational age was 8 weeks and 3 days. She was pregnant without the use of any drugs for induction of ovulation. By ultrasound examination, an intrauterine gestational sac with a sub chorionic hematoma 30mm in its periphery was visible. Gestational age based on Crown-rump length (CRL) of 22mm was 9 weeks with fetal heart rate (FHR) and yolk sac and a fetus in left adnexa had CRL of 21mm or 8 weeks and 6 days without FHR. In the periphery of the adnexal sac was the collection 62×58×68mm (left hematosalpinx). There was moderate fluid in the pelvis and peritoneal cavity (Figure 1).

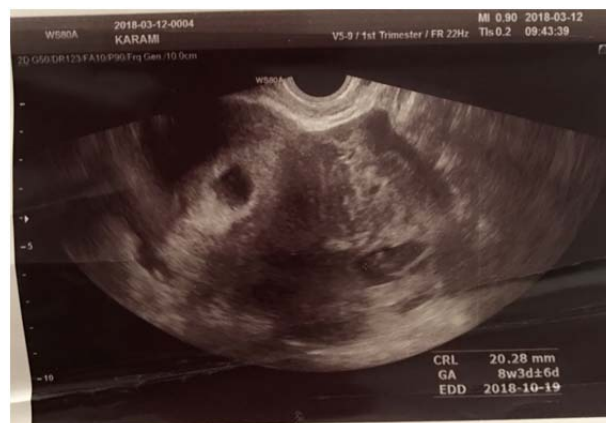Because of acute abdomen and high suspicious of heterotopic pregnancy laparotomy was performed and in the peritoneal cavity was 1000cc blood and 500cc clot in around of left adnexa and in cul-de-sac. Left fallopian tube was ruptured and bleeding. Left salpingectomy and peritoneal washing were

performed (Figure 2).

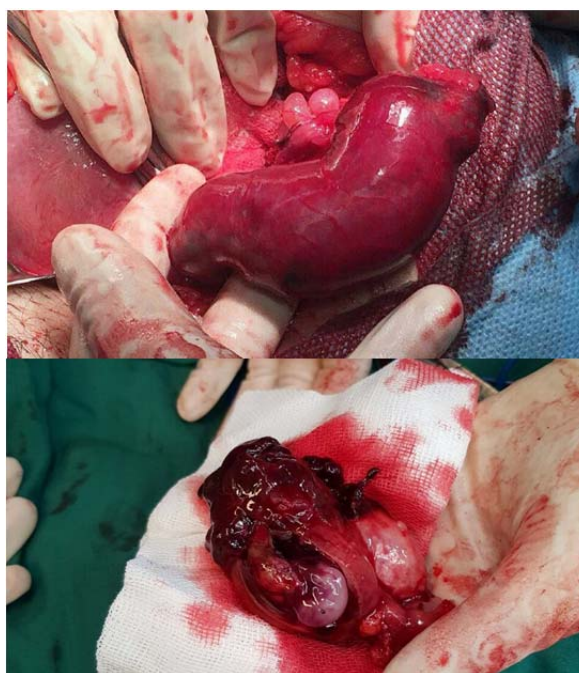
A 17-alpha-hydroxyprogesterone caproate injection was prescribed before surgery and then weekly until tenth weeks of pregnancy.

The ultrasound in the day after surgery showed a viable fetus.

In the pathology report left tubal pregnancy was confirmed.



**Figure 1)** The ultrasound examination reveals simultaneous intra and extra uterine pregnancy



**Figure 2)** Left tubal pregnancy

### Discussion

Heterotopic pregnancy is very rare, although its prevalence has probably increased due to the emergence of assisted reproductive technology (ART). The patient, in this case, was pregnant spontaneously.

Diagnosis of this condition is difficult due to the existence of the intrauterine gestational sac. The most frequent danger lies in the non-recognition of the condition and subsequent rupture of the fallopian tube.

A few case reports have described the treatment of heterotopic cesarean scar viable pregnancies or bilateral tubal ectopic pregnancies [10] with local injection of potassium chloride. This method is commonly used for fetal reduction in multiple pregnancies [6-8], but in our cases expectant or medical management because of the diagnosis of acute abdomen is not feasible. However treatment with potassium chloride is associated with an increased risk of abdominal pain, pregnancy loss, excessive vaginal bleeding, prematurity, need for subsequent surgery, and spontaneous rupture of membranes and subsequent chorioamnionitis [9].

In this patient, the same as the case of Headley and Adum [11], the diagnosis of heterotopic pregnancy was very soon after admission and confirmed after laparotomy and pathology result.

We followed the patient and the last ultrasound examination performed in 20 August, showed a normal fetus with gestational age of 31 weeks and 5 days.

Because this study was a case report, there was no limitation.

### Conclusion

Clinicians should always consider heterotopic pregnancy in the differential diagnosis in a reproductive age patient with abdominal pain and signs or symptoms of ectopic pregnancy. A high index of suspicion for early and timely diagnosis and management with laparotomy or laparoscopy can result in a favorable successful outcome.

**Acknowledgments:** We thanks all the nurses of own department in Firoozgar hospital.

**Ethical Permission:** In Firoozgar hospital as a routine all patients fill out a consent form and this patient signed the form for using her information.

**Conflict of Interests:** There is no conflict of interests.

**Authors' Contribution:** Javanmanesh F. (First author), Introduction author/ Original researcher/ Discussion author (50%); Moeini M. (Second author), Introduction author/ Original researcher/ Discussion author (50%)

**Funding:** There is no sponsor.

### References

- 1- Poujade O, Ducarme G, Luton D. Cornual heterotopic pregnancy: A case report. *J Med Case Rep.* 2009;3:7233.
- 2- Pisarska MD, Carson SA. Incidence and risk factors for ectopic pregnancy. *Clin Obstet Gynecol.* 1999;42(1):2-8.
- 3- Tal J, Haddad S, Gordon N, Timor-Tritsch I. Heterotopic pregnancy after ovulation induction and assisted reproductive technologies: A literature review from 1971 to 1993. *Fertil Steril.* 1996;66(1):1-12.
- 4- Anderson J, Patterson C, Riley A. Heterotopic interstitial pregnancy: A case report. *Case Rep Womens Health.* 2018;17:8-10.
- 5- Jiang Y, Chen J, Zhou H, Zheng M, Han K, Ling J, et al. Management and obstetric outcomes of 17 heterotopic interstitial pregnancies. *BMC Pregnancy Childbirth.* 2018;18:78.
- 6- Brown NE, Singer SA, Suyama J. Delayed detection of spontaneous bilateral tubal ectopic pregnancies after methotrexate treatment. *J Emerg Med.* 2017;53(4):563-7.
- 7- Timor-Tritsch IE, Monteagudo A. Unforeseen consequences of the increasing rate of cesarean deliveries: Early placenta accreta and cesarean scar pregnancy, a review. *Am J Obstet Gynecol.* 2012;207(1):14-29.
- 8- Mohammed ABF, Farid I, Ahmed B, Ghany EA. Obstetric and neonatal outcome of multifetal pregnancy reduction. *Middle East Fertil Soc J.* 2015;20(3):176-81.
- 9- Al-Shelaly UE, Al-Mousa NH, Kurdi WI. Obstetric outcomes in reduced and non-reduced twin pregnancies, a single hospital experience. *Saudi Med J.* 2015;36(9):1122-5.
- 10- Vikhareva O, Nedopekina E, Herbst A. Normal vaginal delivery at term after expectant management of heterotopic caesarean scar pregnancy: A case report. *J Med Case Rep.* 2018;12(1):179.
- 11- Headley AJ, Adum V. Naturally occurring heterotopic pregnancy in a multiparous patient: A case report. *J Reprod Med.* 2013;58(11-12):541-4.